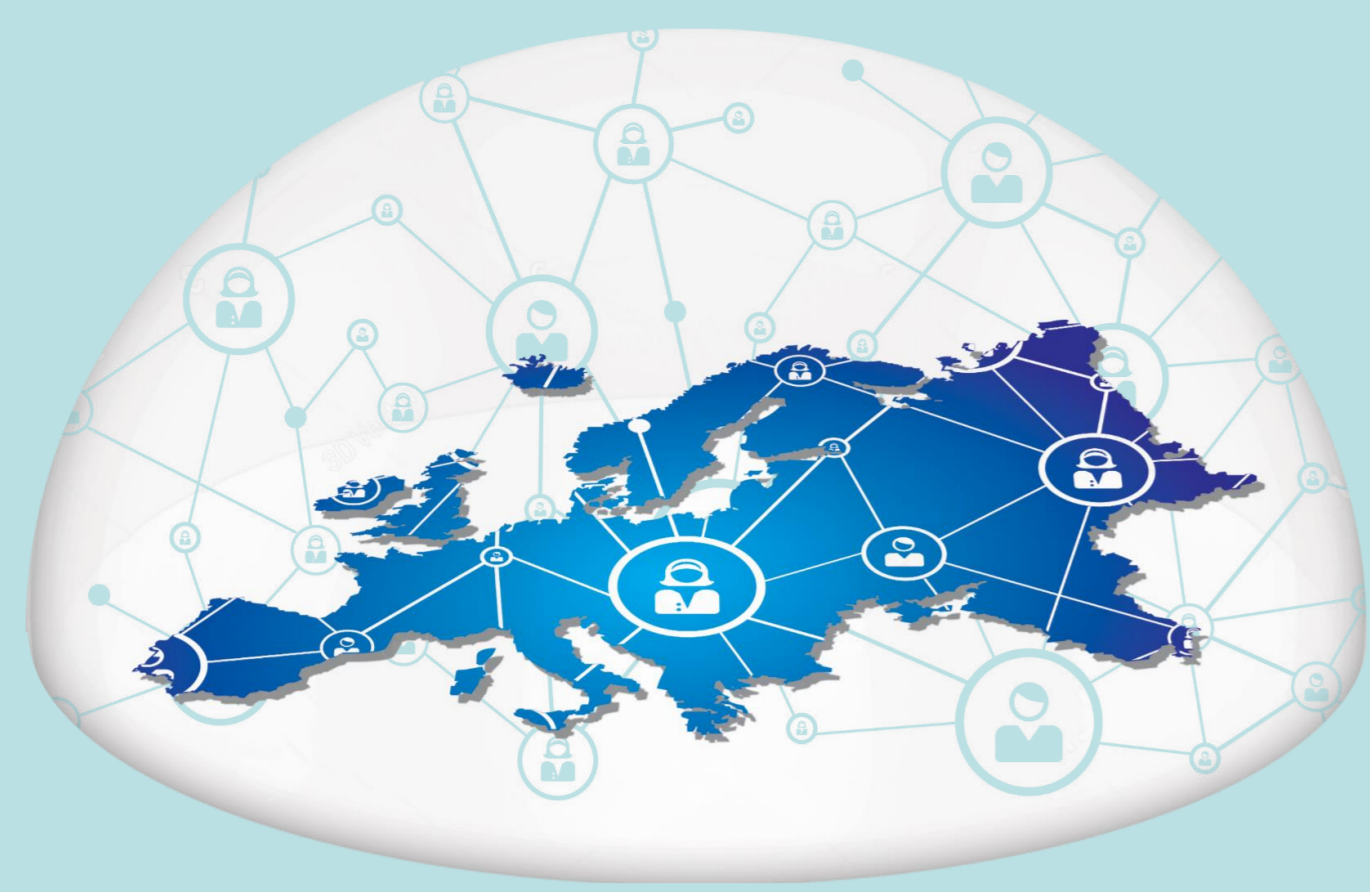



## Current Advances of Ultrasound Diagnosis Technology on Sports Injury Detection and Health Protection

**Yang Song**

Óbuda University, Doctoral School on Safety and Security Sciences, Hungary  
yang.song@uni-obuda.hu

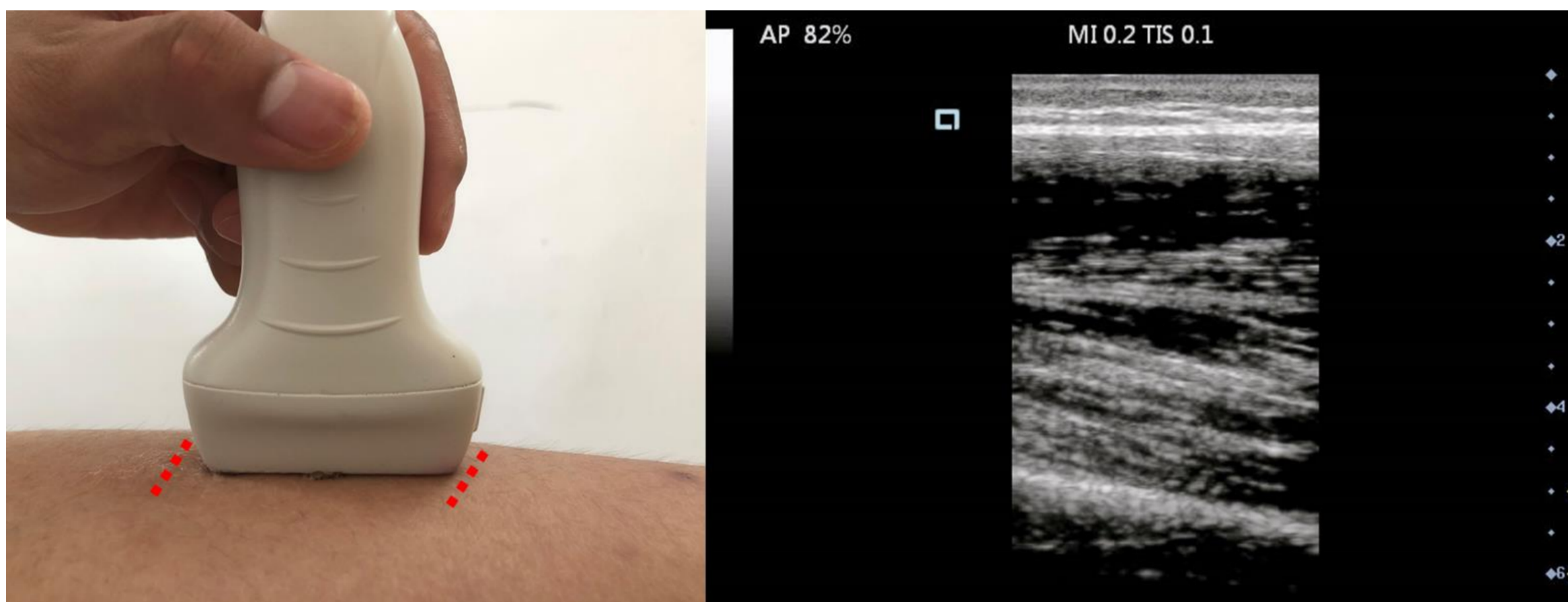
### Introduction

Computed tomography (CT) and magnetic resonance imaging (MRI) technology is wide used for medical imaging diagnosis in sports medicine field. Ultrasound with the advantage of noninvasive, cost-effective and allows assessment of soft tissue pathology. Due to the technological advances in ultrasound equipment and the production of small machines that can be carried to the stadium or sports court, the ultrasound examination and diagnosis for sports-related injuries has been an upsurge of interest. High resolution ultrasound has been commonly used as a screening imaging tool in the past two decades, for the consideration of price and portability.

Ultrasound has developed as a reliable method for imaging of both the upper and lower extremities. The common injuries examined by ultrasound apparatus including hamstring injuries, quadratus injuries, groin injuries patella tendonosis, Achilles tendonosis, rotator cuff tears, epicondylitis at the elbow and tendon abnormalities around the wrist. However, the conflict results were reported from studies, as some tissue can't be able to visualized directly using ultrasound, such as anterior cruciate ligament. The implement of ultrasound diagnosis technology in upper and lower limbs was discussed in this narrative literature review.

### Review study

Generally, musculoskeletal ultrasound with an ultrasonic frequency of 5-20 million cycles/s, and the sound is delivered from a linear array of transmitters and receivers. The reflected waved was sent and received alternately in the equipment. A hand-held probe is utilized with gelatinous transmission fluid to facilitate surface adherence during the diagnosis procedure (Figure 1).



**Fig. 1.** Probe position (Left) and measuring method of ultrasound imaging data (Right) (Take quadriceps femoris for example)

In terms of ultrasound evaluation of the upper-limb sports injuries, this technology could be used for the diagnosis of lateral epicondylitis, providing the information of the severity of disease. Specifically, tendon compressibility and compressibility of intra-tendinous vessels are identified as the main factors for the sonographic assessment of lateral epicondylitis. Besides, sonography was also an effective imaging tool for shoulder subacromial bursitis injections and aspirations.

Due to the nature of sports, such as violent eccentric muscle contractions, muscles, tendons, and ligaments have been found to be the most vulnerable soft tissue, especially for the lower extremity. Therefore, it is of great importance to clarify the evaluation role of ultrasound in lower-limb muscles, tendons, and ligaments. Several common lower-limb muscle groups, such as quadriceps femoris, biceps femoris, and gastrocnemius, are vulnerable during exercise, as they contribute to most of the lower-limb motor functions. Based on the severity of muscle injuries and their corresponding ultrasound imaging, they can be categorized into three degrees. The first degree muscle injuries is subtle, only small change in pennate pattern can be found by ultrasound evaluation. However, muscles would be torn to varying levels in the reminding two degree injuries, even the full-thickness rupture. Studies has demonstrated that ultrasound can offer the real time monitoring regarding the muscle injury healing by visualizing the change of echogenicity and perimysium in the injured muscles. It has been demonstrated that uninjured tendons always present a hyper-echoic fibrillar echo texture.

Similar to muscles, tendon injuries can also be categorized into several degrees based on the severity. It has been found that partial tendon tears may be seen within hypo-echoic while complete tendon tears would be characterized by anechoic hematoma. Quadriceps tendon, patellar tendon, and Achilles tendon were found to be the most involved vulnerable tendon of the lower extremity in previous studies. With the help of ultrasound, any alteration in blood flow or echogenicity can be depicted so as to determine the possible tendon injuries.

Although the ligament has a similar histology with the tendon, their ultrasound may usually present opposite echogenicity (hyper-echoic for the tendon while hypo-echoic for the ligament). In addition, for some deep or intra-articular ligaments, it may not possible for ultrasound to provide direct evaluation due to the physical obstacle. For instance, the anterior cruciate ligament (ACL) is a ligament that may not visualized on ultrasound. Nevertheless, ligaments around knee and ankle joints were the focus for previous studies regarding the ultrasound examination of lower-limb sports injuries. Numerous studies have discussed the accuracy of ultrasound, and it has been demonstrated that hematoma, which can be detected by ultrasound, could be a strong indirect indicator for acute ACL injury.

### Conclusion

Overall, sonographic image evaluation is a reliable and handy method for initial examination of acute or chronic sports injuries. Most muscle injuries can be assessed and graded using ultrasound apparatus. Nevertheless, diversified tools, such as magnetic resonance imaging, should be combined together for further and comprehensive sports injury assessment and health management.

### Acknowledgement

We acknowledge the support of this work by the Óbuda University